
PRESENTING CLINICAL SIGNS

History: Occasional cough. No obvious murmur but difficult to hear heart sounds (overweight). Radiographs show an enlarged cardiac silhouette. Started on pimobendane.

DATE

11/25/21

ECHOCARDIOGRAPHIC FINDINGS

Multiple 2D, M-mode, and Doppler video loops and still images are submitted for review.

PERFORMED BY:

Dr. Mark vanCampen

There is mild left atrial dilation. The mitral valve leaflets are mildly thickened, and there is Doppler evidence of mitral regurgitation present. There is mild left ventricular dilation. Left ventricular systolic function is normal. The aorta and aortic valve are normal. Right atrial and right ventricular dimensions are normal. The tricuspid valve leaflets are mildly thickened, and there is Doppler evidence of tricuspid regurgitation present. TR velocity does not suggest the presence of pulmonary hypertension. The pulmonary artery and pulmonic valve are normal. No heartworms are visualized. No pericardial effusion or cardiac masses are seen.

INTERPRETED BY

 Keith Blass, DVM,
 MS, DACVIM
 (Cardiology)

ECG during echo: Sinus rhythm

PATIENT

Chester2 Roberts

LA/Ao - 1.83
 LVIDd - 44.5 mm
 LVIDs - 31.4 mm
 FS - 29.4%
 LVOT - 1.20 m/s
 RVOT - 0.69 m/s
 TR - 2.50 m/s

SPECIES

Canine

ASSESSMENT/RECOMMENDATIONS

Degenerative mitral and tricuspid valve disease

BREED

Border Collie Mix

This examination demonstrates regurgitation of blood across Chester's mitral and tricuspid valves resulting from degenerative valve disease. Chester's tricuspid valve disease is mild, as evidenced by his absence of secondary right heart chamber dilation. His mitral valve disease is a bit more advanced, as Chester has mild dilation of both his left atrium and left ventricle, though his left ventricular systolic function is normal. As only mild left heart chamber dilation is present, Chester's mitral valve disease appears to be well-compensated, and it's unlikely that his disease is contributing to his occasional cough.

SEX

MN

Continued use of pimobendan (7.5 mg BID) is warranted based on this exam. A cough suppressant, such as hydrocodone, may be given if Chester's cough is significant enough to warrant therapy.

AGE

13 y

A recheck echocardiogram is recommended in 9 months. Repeat thoracic radiographs are recommended if clinical signs compatible with congestive heart failure develop.

WEIGHT

25.4 kg

HOSPITAL NAME

Mississippi Mills AH

REFERRING VET

Dr. vanCampen



DATE

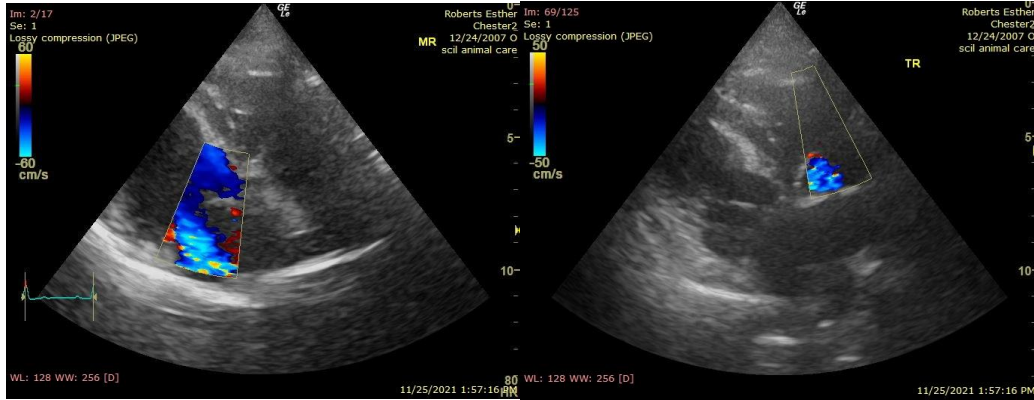
11/25/21

PERFORMED BY:

Dr. Mark vanCampen

INTERPRETED BY

Keith Blass, DVM,
MS, DACVIM
(Cardiology)



The information and recommendations provided are based on the images presented by the referring veterinarian. No evaluation can be communicated regarding pathology that was not visible in the image/video clips provided.

PATIENT

Thank you for this referral. If the clinical or image interpretation does not parallel your findings or if I can be of any further assistance please contact me.

Chester2 Roberts

SPECIES

Keith Blass, DVM, MS, DACVIM (Cardiology)
KeithBlass@gmail.com
631-804-5754

Canine

BREED

Border Collie Mix

SEX

MN

AGE

13 y

WEIGHT

25.4 kg

HOSPITAL NAME

Mississippi Mills AH

REFERRING VET

Dr. vanCampen